

## RESEARCH REPORT

# Limbic and Frontal Cortical Degeneration Is Associated with Psychiatric Symptoms in *PINK1* Mutation Carriers

Kathrin Reetz, Rebekka Lencer, Susanne Steinlechner, Christian Gaser, Johann Hagenah, Christian Büchel, Dirk Petersen, Norman Kock, Ana Djarmati, Hartwig R. Siebner, Christine Klein, and Ferdinand Binkofski

**Background:** Mutations in the *PINK1* gene can cause Parkinson's disease and are frequently associated with psychiatric symptoms that might even precede motor signs.

**Methods:** To determine whether specific gray matter degeneration of limbic and frontal structures might be liable to different psychiatric symptoms in *PINK1* mutation carriers, observer-independent voxel-based morphometry was applied to high-resolution magnetic resonance images of 14 *PINK1* mutation carriers from a large German family and 14 age- and gender-matched healthy control subjects.

**Results:** Psychiatric diagnoses in *PINK1* mutation carriers comprised major depression without psychotic symptoms and schizophrenia-spectrum, panic, adjustment, and obsessive-compulsive personality disorders. As hypothesized, the categorical comparison between all *PINK1* mutation carriers and control subjects demonstrated atrophy of limbic structures, especially the hippocampus and parahippocampus. More specifically, multiple regression analysis considering all psychiatric subscores simultaneously displayed different frontal (prefrontal, dorsolateral, and premotor cortex) and limbic (parahippocampus and cingulate) degeneration patterns. The duration of the psychiatric disease was also correlated with the extent of limbic and frontal gray matter volume decrease.

**Conclusions:** Our results support the hypothesis that limbic and frontal gray matter alterations could explain various psychiatric symptoms observed in *PINK1* mutation carriers. Factors determining individual susceptibility to degeneration of certain brain areas remain to be elucidated in future studies.

**Key Words:** Hippocampus, Parkinson's disease, *PINK1*, psychiatric disorders, voxel-based morphometry

Parkinson's disease (PD) is a common, slowly progressive neurodegenerative disorder. Although characterized by its motor symptoms, recent findings point to the impact of mental impairment and psychiatric symptoms in PD patients (1). Although the origin of the disease in the majority of PD patients currently remains unknown, approximately 2%–3% of all cases can be explained by a monogenic cause. To date, there is evidence for at least six genes being associated with monogenic PD (2). Mutations in the *PINK1* gene are the second common known single factor responsible for early-onset PD (3) and can lead to a phenotype indistinguishable from that of idiopathic PD (3–5).

A number of studies support the hypothesis that psychiatric disorders are associated with an increased risk of PD (6–9). The most common psychiatric syndrome seen in PD is depression (10), followed by psychotic symptoms (11), anxiety syndromes, or cognitive impairment (11), which can antedate motor symptoms by several years (6). Psychiatric symptoms in genetically determined PD syndromes have been described in *Parkin* and

*PINK1* mutation carriers (*PINK1*-MC) (12–14). Recently, we reported about the clinical spectrum covering both neurological and psychiatric symptoms in a large German pedigree with *PINK1*-associated PD (5,15). Systematic evaluation revealed that psychiatric disorders were present in 72% of the homozygous and heterozygous *PINK1*-MC and had mostly preceded the manifestation of PD motor signs (15).

The aim of the present study was to evaluate whether the psychiatric symptoms observed in the *PINK1*-MC could be explained by specific gray matter volume (GMV) alterations in brain areas that are suggested to be involved in disease mechanisms of psychiatric disorders. Following an explorative approach based on previously published morphometric data in affective disorder, schizophrenia, and anxiety disorder, we hypothesized that limbic and frontal structures would be of special interest.

## Methods and Materials

We compared structural magnetic resonance images (MRI) (T1-weighted three-dimensional [3D] magnetization prepared rapid acquisition gradient echo [MPRAGE]) of 14 *PINK1*-MC (5 female, mean age: 49.6 years [ $\pm$  12.6]) with those of 14 age- and gender-matched healthy control subjects (5 female, mean age: 49.0 years [ $\pm$  10.7],  $p = .90$ ). All subjects gave their written informed consent for participation in this study, which was approved by the ethics committee of the University of Luebeck. The *PINK1*-MC belonged to a large family originating in the southwestern part of Germany and were identified as part of large-scale genetic studies (16–18). Although 4 individuals (II.1, II.3, II.5, and II.7) were homozygous for the 1366C>T mutation in *PINK1*, the remaining 10 carried only one mutated allele and were therefore heterozygous. We have to note that our subjects were only screened for a mutation in the *PINK1* gene.

All control subjects had a normal neurological and psychiatric examination and tested negative for the *PINK1* mutation.

From the Department of Neurology (KR, JH, NK, AD, CK, FB); Department of Psychiatry and Psychotherapy (RL, SS); Institute of Neuroradiology (DP), University of Luebeck, Luebeck; Neurolmage Nord (KR, CB, HRS, FB), Hamburg-Luebeck-Kiel; Department of Systems Neuroscience (CB), University Medical Center Hamburg Eppendorf, Hamburg; Department of Psychiatry (CG), University of Jena, Jena; and the Department of Neurology (HRS), Christian-Albrechts-University, Kiel, Germany. The first two authors contributed equally to the study.

Address reprint requests to Ferdinand Binkofski, M.D., Department of Neurology, University of Luebeck, Ratzeburger Allee 160, 23538 Luebeck, Germany; E-mail: ferdinand.binkofski@neuro.uni-luebeck.de.

Received August 27, 2007; revised December 11, 2007; accepted December 14, 2007.

### Neurological Motor Examination

All participants underwent a detailed neurological examination by a blinded movement disorder team. The videotaped assessment of the Unified Parkinson's Disease Rating Scale (UPDRS) part III protocol was blindly evaluated by an independent movement disorder specialist (5,15). The diagnosis of definite PD was based on the United Kingdom Brain Bank diagnostic criteria.

All four homozygous *PINK1*-MC manifested definite clinical motor signs (5), received a dopaminergic medication, and were tested in the on-phase. Two of the heterozygous *PINK1*-MC showed signs of probable PD, and another four of them showed signs of possible PD. All of them were unaware of these signs. The remaining four heterozygous *PINK1*-MC were clinically unaffected.

### Psychiatric Examination

To assess lifetime Axis I (clinical) and Axis II (personality) psychiatric disorders, one of two experienced psychiatrists, who were blind with respect to the individual's neurological diagnosis and mutational status, administered the German version of the Structured Clinical Interview for DSM-IV (15). Diagnoses were confirmed at consensus conferences with a third senior psychiatrist, considering all available clinical data, including information on the medical health status. Diagnoses comprised major depression without psychotic symptoms, schizophrenia-spectrum disorders, panic disorder, adjustment disorder, and obsessive-compulsive personality disorder (OCPD; Table 1) (15). None of the *PINK1*-MC or control subjects showed evidence for cognitive impairment (mean Mini Mental State Examination score: 28.9 [ $\pm$ .9]).

For the purpose of the parametric regression analysis with structural data, psychiatric disorder scores were defined with a value of "2" encoding definite and "1" encoding probable affection. Multiple regression analysis including the individual diagnostic scores for each subject was used to evaluate potential interactions and account for the fact that five subjects were diagnosed with a combination of at least two psychiatric disorders.

### MRI Scanning

Scanning was performed on a 1.5-T whole-body scanner (Symphony; Siemens, Erlangen, Germany). All subjects under-

went MRI imaging with a  $T_1$ -weighted FLASH-3D MR sequence (echo time [TE] = 5 msec; repetition time [TR] = 15 msec; flip angle = 30°; isotropic voxel size  $1 \times 1 \times 1 \text{ mm}^3$ ). Images were analyzed with voxel-based morphometry (VBM), a fully observer-independent automated technique for computational analysis of differences in local GMV with SPM2 (Wellcome Department of Imaging Neuroscience, Institute of Neurology, UCL, London, United Kingdom), for further details of the procedure, please see (19).

The spatial normalization to the standard anatomical space was performed in a two-stage process. First, we registered each image to the International Consortium for Brain Mapping Template (Montreal Neurological Institute [MNI], Montreal, Canada). We applied a 12-parameter affine transformation to correct image size and position. Regional volumes were preserved, while corrections for global differences in whole-brain volume were made. All normalized images were averaged and smoothed with a Gaussian kernel of 8 mm full-width at half maximum (FWHM) and then used as a new template with reduced scanner- and population-specific bias. Second, we locally deformed each image to the new template with a nonlinear spatial transformation. With a modified mixture-model-cluster analysis, normalized images were corrected for non-uniformities in signal intensity and partitioned into gray and white matter, cerebrospinal fluid (CSF), and background. To remove unconnected non-brain voxels, we applied a series of morphological erosions and dilations to the segmented images (20). A gray matter mask was used to reduce edge effects around the ventricles, meninges, and veins. Finally, images were smoothed with a Gaussian kernel of 12 mm FWHM.

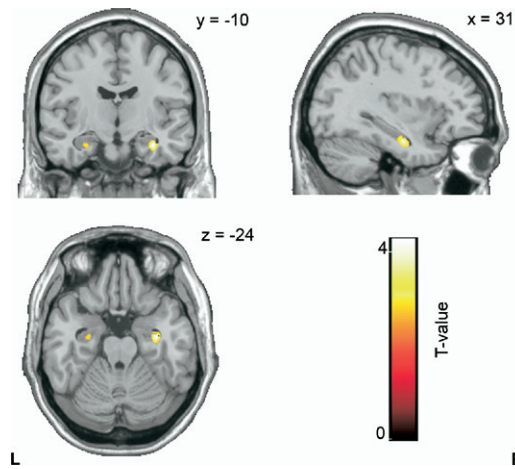
### Statistical Analysis

A voxel-by-voxel one-way analysis of variance (ANOVA) was computed to detect differences in GMV between groups and with an absolute gray matter threshold of .25 to avoid possible edge effects around the border between gray and white matter or CSF. On the basis of previous morphometric data in patients with these psychiatric disorders (21–27), we hypothesized reduced GMV in: 1) limbic structures (hippocampus, parahippocampus, and cingulate); and 2) the frontal lobe (dorsolateral, frontomesial, and fronto-orbital areas).

First, an explorative categorical comparison was calculated between the 14 *PINK1*-MC and their control subjects. Although

**Table 1.** Demographic Data and Clinical Findings in 14 *PINK1* Mutation Carriers

Code	Age	Gender	Genetic Status	Duration of Psychiatric Disorder	Major Depression	Schizophrenia Spectrum-Disorder	Panic Disorder	Adjustment Disorder	Obsessive-Compulsive Personality Disorder	Summarized Psychiatric Score
III.1	50	M	heterozygous	27	0	2	0	0	0	2
II.5	68	W	homozygous	15	2	0	0	0	2	4
II.3	69	W	homozygous	0	0	0	0	0	0	0
II.7	60	W	homozygous	20	2	0	2	0	0	4
III.11	31	M	heterozygous	4	2	0	2	0	0	4
II.1	71	W	homozygous	28	2	0	0	0	0	2
III.5	43	M	heterozygous	25	0	1	0	0	0	1
III.10	47	M	heterozygous	0	0	0	0	0	0	0
III.8	39	M	heterozygous	21	0	0	0	0	2	2
III.9	35	M	heterozygous	0	0	0	0	0	0	0
III.3	47	W	heterozygous	18	2	1	0	0	0	3
III.4	45	W	heterozygous	24	0	2	0	2	0	4
III.6	45	M	heterozygous	1	0	0	0	2	0	2
III.7	44	M	heterozygous	0	0	0	0	0	0	0



**Figure 1.** The categorical comparison between 14 *PINK1* mutation carriers (*PINK1*-MC) and healthy control subjects revealed a decrease in *PINK1*-MC in limbic structures, in particular in the right hippocampus adjacent to the parahippocampus ( $p < .01$ , uncorrected).

we were aware of the small sample sizes of psychiatric subgroups, we performed an ANOVA including the five subgroups and control subjects and tested post hoc for comparisons between individual psychiatric subgroups and control subjects. Second, simple regression analysis considering the duration of the psychiatric disease as exploratory

variable and a multiple regression analysis considering all individual sub-scores simultaneously were performed. For the specification of the psychiatric regression analyses, the clinical motor score (UPDRS III) was included in the multiple regression analysis.

To correct for multiple comparisons, we applied the False Discovery Rate (FDR) approach, which controls the expected proportion of false positives among suprathreshold voxels (28). The threshold used was  $p < .05$ . According to our a priori hypotheses, a small volume correction (SVC) with a sphere of 10 mm was carried out. The Wake Forest University (WFU) PickAtlas (29) was taken as an anatomical reference.

## Results

### Categorical Comparisons

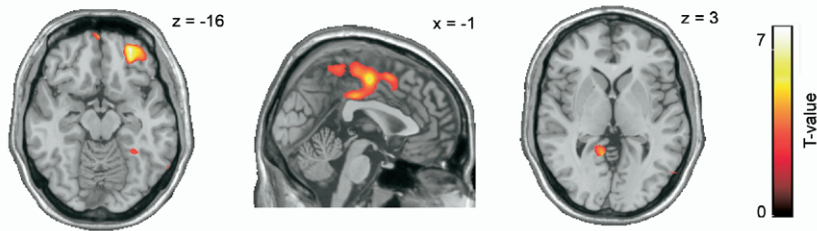
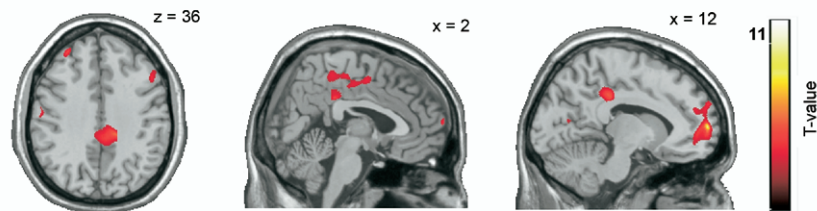
The categorical comparison (ANOVA) between *PINK1*-MC and control subjects revealed GMV decreases in limbic structures like the right hippocampus and the adjacent parahippocampal gyrus (Figure 1; Table 2). Post hoc pairwise comparisons between distinct psychiatric subgroups and control subjects showed a significant GMV decrease of the parahippocampal gyrus in both the schizophrenia-spectrum and the adjustment-disorder subgroups. For the OCPD subgroup, we found a GMV reduction mostly in frontal structures like dorsolateral and prefrontal cortex (PFC) and right insula on the one hand and in limbic cingulate on the other (Table 2).

**Table 2.** Categorical Comparisons—Coordinates and Gray Matter Values in 14 *PINK1*-Mutation Carriers

Regions	Side	MNI Coordinates (mm)			T-Value	Z Score	SVC $p_{FDR}$
		x	y	z			
<b>Analysis of Variance</b>							
<i>PINK1</i> -MC < Control Subjects							
Limbic structures							
Hippocampus	R	31	-10	-24	4.01	3.51	.041
Parahippocampa gyrus	R	31	-13	-24	3.57	3.19	.041
Post Hoc Comparisons: Psychiatric Subgroup < Control Subjects							
Major depression score <sup>a</sup>							
Schizophrenia-spectrum score							
Limbic structures							
Parahippocampa gyrus	R	31	-10	-24	4.09	3.51	.041
Panic disorder score <sup>a</sup>							
Adjustment disorder score							
Limbic structures							
Parahippocampa gyrus	L	-24	-9	-20	3.49	3.17	.040
Obsessive-compulsive personality disorder score							
Frontal lobe							
Superior frontal gyrus (PFC)	L	-25	55	32	3.92	3.39	.035
Superior frontal gyrus (OFC)	R	35	64	1	3.89	3.38	.022
Superior frontal gyrus (PFC)	R	24	31	56	3.89	3.02	.041
Superior frontal gyrus (PFC)	R	16	46	48	3.08	2.79	.027
Inferior frontal gyrus (vPMC)	R	44	20	26	3.35	2.99	.040
Medial frontal gyrus (paracentral lobule)	L	-5	-29	55	3.11	2.81	.028
Inferior frontal gyrus (anterior insula)	R	36	31	-4	4.04	3.48	.020
Precentral gyrus (PMC)	L	-58	-9	33	3.24	2.91	.016
Limbic structures							
Middle cingulate gyrus	L	-9	-40	42	3.58	3.16	.050
Posterior cingulate gyrus	R	14	-51	9	3.16	2.85	.041

*PINK1*-MC, *PINK1* mutation carriers; MNI, Montreal Neurological Institute; SVC, small volume correction; FDR, false discovery rate; PFC, prefrontal cortex; OFC, orbital frontal cortex; (v)PMC, (ventral) premotor cortex.

<sup>a</sup>No significant results.

**A) Regression analysis with disease duration****B) Regression analysis with all individual psychiatric disorder scores**

**Figure 2.** (A) Simple regression analysis, including the morphometric data of the 14 *PINK1* mutation carriers (*PINK1*-MC) with the disease duration revealed degeneration in the mesial frontal structures and the limbic parahippocampus bilaterally. (B) Multiple regression analysis with all individual psychiatric subscores displayed degeneration patterns including also frontal (prefrontal, dorsolateral, and premotor frontal cortex) and limbic (parahippocampus and cingulate) structures ( $p < .01$ , uncorrected).

L

R

### Simple Regression Analysis With Duration of Psychiatric Symptoms

Most of the disease duration-related GMV decrease was found in the right orbitofrontal cortex, dorsal premotor cortex (PMC) and supplementary motor area, and the parahippocampal gyrus bilaterally (Figure 2A; Table 3).

### Multiple Regression Analysis Including Individual Psychiatric Sub-Scores

Considering the severity of specific psychiatric symptoms by multiple regression analysis with all individual psychiatric scores simultaneously revealed a significant GMV decrease in the frontal lobe, in particular in the right dorsolateral and mesial PFC and PMC. Regarding the limbic system, the right posterior cingulate and left parahippocampus were affected (Figure 2B; Table 3). The single regression analyses for each psychiatric subgroup, which can be regarded as post hoc procedures after the multiple regression analysis, yielded a decrease in GMV of limbic (posterior cingulate and parahippocampus) and frontal structures (orbitofrontal, mesio-lateral frontal, or dorsolateral and PFC and right insula) for the schizophrenia-spectrum, the panic disorder, and the OCPD subgroups. The adjustment disorder score was correlated with a reduction of only frontal structures (PFC), whereas no correlation was seen for the major depression subgroup (Table 3).

### Discussion

Investigating a potential association of GMV alterations with lifetime prevalence of different psychiatric disorders represents an innovative approach to unraveling the underlying disease mechanisms in mental illness. An observer-independent explorative approach to discover subtle, regionally specific GMV alterations (15) revealed an association between different psychiatric disorders and distinct patterns of limbic and frontal GMV degeneration. These findings might thus contribute to a better understanding of the underlying etiologic mechanisms of psychiatric symptoms that are frequently reported in *PINK1*-associated PD and that might even become manifest before motor signs. Because our study group consisted of carriers of one or

two mutated alleles of the *PINK1* gene, additional hypotheses might be raised considering the potential role of a heterozygous mutation not only in the development of Parkinsonism but also of psychiatric disease.

Specifically, there were two major findings. First, a GMV reduction of limbic structures, in particular in the hippocampus and parahippocampal gyrus, was observed in the group of *PINK1*-MC, irrespective of their psychiatric status, when compared with the control subjects. Second, in *PINK1*-MC, distinct GMV degenerations in limbic and frontal structures were correlated with both the occurrence of psychiatric disorders and also with the duration of the psychiatric disease. On the basis of knowledge about the functional impact of certain limbic and frontal structures, it seems possible to interpret our findings as discussed in the following sections.

### Limbic Structures

The most striking and consistent finding was that of GMV reductions in the hippocampus, parahippocampus, and cingulate, especially its posterior part, in both the categorical comparisons (ANOVA) and the multiple regression analysis considering all individual psychiatric sub-scores. Of note, the parahippocampal GMV decrease bilaterally was also correlated with the disease duration. Post hoc analyses suggested that a limbic GMV decrease might be particularly present in schizophrenia-spectrum disorders, panic disorder, adjustment disorder, and OCPD.

The hippocampus and the parahippocampal region represent central components of the limbic system and have complex interconnections with regions involved in emotional processing. Atrophy of the hippocampus has been described in a variety of psychiatric disorders (24,26,30–36) regarding schizophrenia; a reduction of hippocampal and parahippocampal structures is the most consistent finding (23). There is evidence that hippocampal atrophy even precedes the development of psychiatric symptoms, although it remains unclear to what extent hippocampal atrophy plays a role in the genesis of psychiatric symptoms and their progression (37).



**Table 3.** Regression Analyses—Coordinates and Gray Matter Values in 14 *PINK1*-Mutation Carriers

Regions	Side	MNI Coordinates (mm)			T-value	Z Score	SVC $p_{FDR}$
		x	y	z			
<b>Simple Regression Analysis With Duration of the Psychiatric Disorders</b>							
<b>Frontal lobe</b>							
Superior frontal gyrus (OFC)	R	25	49	-16	7.10	4.37	.001
Superior frontal gyrus (dPMC)	R	26	-8	70	4.03	3.14	.046
Medial frontal gyrus (SMA)	L	-3	-11	53	5.75	3.91	.003
<b>Limbic structures</b>							
Parahippocampal gyrus	R	28	-43	-15	3.73	2.98	.041
Parahippocampal gyrus	L	-15	-46	-6	3.36	2.77	.035
<b>Multiple Regression Analysis Considering All Individual Psychiatric Sub-Scores</b>							
<b>Frontal lobe</b>							
Middle frontal gyrus (DLPFC)	R	43	29	43	10.28	4.50	.002
Medial frontal gyrus (mesial PFC)	R	12	62	8	11.9	4.73	.002
Inferior frontal gyrus (frontal operculum, Broca's homologue)	R	61	13	22	7.33	3.94	.010
Precentral gyrus (PMC)	L	-59	-11	32	5.07	3.30	.037
<b>Limbic structures</b>							
Posterior cingulate gyrus	R	12	-33	36	5.76	3.53	.008
Parahippocampal gyrus	L	-17	-52	-1	6.43	3.72	.017
<b>Single Regression Analysis in Major Depression Score<sup>a</sup></b>							
<b>Single Regression Analysis in Schizophrenia-Spectrum Score</b>							
<b>Frontal lobe</b>							
Superior frontal gyrus (OFC)	R	20	50	-20	5.83	3.54	.050
<b>Limbic structures</b>							
Posterior cingulate gyrus	R	14	-32	37	4.84	3.22	.039
Parahippocampal gyrus	L	-17	-53	0	6.99	3.96	.026
<b>Single Regression Analysis in Panic Disorder Score</b>							
<b>Frontal lobe</b>							
Medial frontal gyrus (mesiofrontal cortex)	R	12	62	8	10.64	4.55	.007
Middle frontal gyrus (DLPFC)	R	43	29	43	8.11	4.11	.014
Middle frontal gyrus (dPMC)	R	36	3	53	5.40	3.41	.039
<b>Limbic structures</b>							
Posterior cingulate gyrus	R	14	-33	37	4.62	3.13	.050
<b>Single Regression Analysis in Adjustment Disorder Score</b>							
<b>Frontal lobe</b>							
Middle frontal gyrus (PFC)	R	29	65	15	8.44	4.18	.012
<b>Single Regression Analysis in Obsessive-Compulsive Personality Disorder Score</b>							
<b>Frontal lobe</b>							
Superior frontal gyrus (PFC)	L	-28	47	41	7.46	3.97	.006
Superior frontal gyrus (mesial PFC)	R	10	23	67	5.22	3.35	.026
Middle frontal gyrus (DLPFC)	R	43	29	43	15.52	5.13	.001
Medial frontal gyrus (mesial PFC)	R	12	62	8	9.27	4.33	.018
Inferior frontal gyrus (anterior insula)	R	39	25	-1	6.18	3.65	.016
Precentral gyrus (PMC)	L	-58	-11	32	6.89	3.83	.005
<b>Limbic structures</b>							
Anterior cingulate gyrus	R	11	50	22	4.65	3.15	.036
Anterior cingulate gyrus	R	9	55	10	3.05	2.41	.018
Parahippocampal gyrus	L	-17	-53	0	10.37	4.51	.001

(d)PMC, (dorsal) premotor cortex; DLPFC, dorsolateral prefrontal cortex; SMA, supplementary motor area; other abbreviations as in Table 2.

<sup>a</sup>No significant results.

The cingulate is attributed with the regulation of emotion and social behavior by integrating neocortical mechanisms of perception, recognition, and thinking with the ventromedial PFC through projections from the amygdalae, brainstem, and hypothalamus (38,39). The posterior cingulate seems to be critically involved in self reflection and information processing during complex cognitive tasks (40), whereas the anterior cingulate is assumed to represent part of a network involving the medial PFC and critical for decision-making and cognition (41). Although our findings must be regarded as preliminary, they are consistent with

the observation that these psychological functions are particularly impaired in schizophrenia spectrum disorders, panic disorder, and OCPD, as suggested by the single regression analyses.

### Frontal Structures

The limbic system interacts with PFC in many respects, and tight interconnections between both systems are assumed. Therefore, it was not surprising to find alterations of mesial and dorsolateral PFC as well as the Broca homologue and the PMC in *PINK1*-MC when compared with control subjects. We found

evidence that GMV reduction in the dorsolateral and mesial PFC as well as the PMC might be associated with the occurrence of panic, adjustment, and OCPD, whereas degeneration of the orbital frontal cortex seems to be related to schizophrenia-spectrum and OCPD. Functionally, the mesial PFC is suggested to play a critical role for social behavior, emotion (39), and social interaction, including reinforcement-guided behavior and learning the value of actions (41). Neuroimaging data show that problems with decision-making are mainly attributable to frontal cortex structures (42), especially the posterior fronto-medial cortex (43). In schizophrenia, orbitofrontal brain volume alterations have been reported besides those in temporal and parietal regions (44,45), which might explain psychopathological symptoms like loss of inhibitory control. With respect to anxiety disorders, the PFC is suggested to mediate phobic avoidance behavior. There is a profound line of evidence that its ventromedial part is involved in mechanisms of anxiety regulation (46) by inhibiting fear responses and enhancing fear extinction (47). In contrast, the dorsolateral PFC is critical for maintaining and manipulating working memory processes. Interestingly, anxiety seems to disrupt certain aspects of working memory, especially spatial working memory (48).

### Disease Duration

The duration of the psychiatric disease yielded a degeneration pattern involving limbic—especially the parahippocampal gyrus—and frontal structures. Highlighting the time dependency of the pathological alterations, this finding underlines the notion of psychiatric symptoms reflecting an ongoing neurodegenerative process involving a broad cortical network. It might further reflect the fact that the *PINK1* gene is broadly expressed throughout the brain (49).

### Conclusions

Although this cross-sectional study is based on a small sample of individuals from one large family, we found evidence for the hypothesis that psychiatric disorders occurring in *PINK1*-MC are associated with distinct GMV degeneration patterns. The functional considerations with respect to limbic and frontal structures might explain why the GMV decrease could lead to increased emotional liability and vulnerability resulting in the manifestation of the observed psychiatric disorders. It remains to be elucidated how an individual susceptibility to degeneration of certain brain areas in *PINK1*-MC is determined by the dysfunction of the *PINK1* protein.

We are aware of the fact that the GMV alterations we observed in our study group could be due to pathological processes other than a *PINK1* mutation and that there is a caveat comparing findings of medically healthy psychiatric patients to those in our *PINK1*-MC. However, currently very little is known about the neuronal correlates of psychiatric disorders and the pathoanatomical processes in medically healthy psychiatric patients, and no study exists on the role of *PINK1* mutations in psychiatric disorders. In the absence of known genetic causes of psychiatric disorders, patients with known genetic mutations associated with psychiatric conditions might therefore serve as a valuable study population to aid in the identification of (genetic) causes of neuro-psychiatric disease.

*The study was supported by grants of the Bundesministerium für Bildung und Forschung Neuroimagingzentrum GF-GO-01GO0205/-206/-207 and BMBF GF-01GW0571 and -01GW0752, the Deutsche Forschungsgemeinschaft (K1-1134-*

*2-2, K1-1134-3-1, RE 2841/1-1), the Parkinson's Disease Foundation, and the EU-FP6-Grant (GENEPARK; EU-LSHB-CT-2006-037544) and EU-FP7-Grant (ROSSI; EU-ICT-2007-1). The authors FB and CK were sponsored by the Volkswagen Foundation and KR (E06-2008) and CK by intramural grants from the Medical Faculty, University of Luebeck.*

*All authors have no conflicts of interest, financial or otherwise, related directly or indirectly to this work.*

- Schrag A (2004): Psychiatric aspects of Parkinson's disease—an update. *J Neurol* 251:795–804.
- Ramirez A, Heimbach A, Grundeman J, Stiller B, Hampshire D, Cid LP, *et al.* (2006): Hereditary parkinsonism with dementia is caused by mutations in ATP13A2, encoding a lysosomal type 5 P-type ATPase. *Nat Genet* 38:1184–1190.
- Klein C, Schlossmacher MG (2006): The genetics of Parkinson disease: Implications for neurological care. *Nat Clin Pract Neurol* 2:136–146.
- Bonifati V, Rohe CF, Breedveld GJ, Fabrizio E, De Mari M, Tassorelli C, *et al.* (2005): Early-onset parkinsonism associated with PINK1 mutations: Frequency, genotypes, and phenotypes. *Neurology* 65:87–95.
- Hedrich K, Hagenah J, Djarmati A, Hiller A, Lohnau T, Lasek K, *et al.* (2006): Clinical spectrum of homozygous and heterozygous PINK1 mutations in a large German family with Parkinson disease: Role of a single hit? *Arch Neurol* 63:833–838.
- Shiba M, Bower JH, Maraganore DM, McDonnell SK, Peterson BJ, Ahlskog JE, *et al.* (2000): Anxiety disorders and depressive disorders preceding Parkinson's disease: A case-control study. *Mov Disord* 15:669–677.
- Gonera EG, van't Hof M, Berger HJ, van Weel C, Horstink MW (1997): Symptoms and duration of the prodromal phase in Parkinson's disease. *Mov Disord* 12:871–876.
- Hubble JP, Cao T, Hassanein RE, Neuberger JS, Koller WC (1993): Risk factors for Parkinson's disease. *Neurology* 43:1693–1697.
- Dooneief G, Mirabello E, Bell K, Marder K, Stern Y, Mayeux R (1992): An estimate of the incidence of depression in idiopathic Parkinson's disease. *Arch Neurol* 49:305–307.
- Oertel WH, Hoglinger GU, Caraceni T, Girotti F, Eichhorn T, Spottke AE, *et al.* (2001): Depression in Parkinson's disease. An update. *Adv Neurol* 86:373–383.
- Aarsland D, Larsen JP, Lim NG, Janvin C, Karlsen K, Tandberg E, *et al.* (1999): Range of neuropsychiatric disturbances in patients with Parkinson's disease. *J Neurol Neurosurg Psychiatry* 67:492–496.
- Hatano Y, Li Y, Sato K, Asakawa S, Yamamura Y, Tomiyama H, *et al.* (2004): Novel PINK1 mutations in early-onset parkinsonism. *Ann Neurol* 56:424–427.
- Khan NL, Graham E, Critchley P, Schrag AE, Wood NW, Lees AJ, *et al.* (2003): Parkin disease: A phenotypic study of a large case series. *Brain* 126:1279–1292.
- Rohe CF, Montagna P, Breedveld G, Cortelli P, Oostra BA, Bonifati V (2004): Homozygous PINK1 C-terminus mutation causing early-onset parkinsonism. *Ann Neurol* 56:427–431.
- Steinlechner S, Stahlberg J, Völkel B, Djarmati A, Hagenah J, Hiller A, *et al.* (2007): Co-occurrence of affective and schizophrenia spectrum disorders with PINK1 mutations. *JNNP* 78:532–535.
- Klein C, Pramstaller PP, Kis B, Page CC, Kann M, Leung J, *et al.* (2000): Parkin deletions in a family with adult-onset, tremor-dominant parkinsonism: Expanding the phenotype. *Ann Neurol* 48:65–71.
- Hedrich K, Kann M, Lanthaler AJ, Dalski A, Eskelson C, Landt O, *et al.* (2001): The importance of gene dosage studies: Mutational analysis of the parkin gene in early-onset parkinsonism. *Hum Mol Genet* 10:1649–1656.
- Kann M, Jacobs H, Mohrmann K, Schumacher K, Hedrich K, Garrels J, *et al.* (2002): Role of parkin mutations in 111 community-based patients with early-onset parkinsonism. *Ann Neurol* 51:621–625.
- Binkofski F, Reetz K, Gaser C, Hilker R, Hagenah J, Hedrich K, *et al.* (2007): Morphometric fingerprint of asymptomatic Parkin and PINK1 mutation carriers in the basal ganglia. *Neurology* 69:842–850.
- Good CD, Johnsrude IS, Ashburner J, Henson RN, Friston KJ, Frackowiak RS (2001): A voxel-based morphometric study of ageing in 465 normal adult human brains. *Neuroimage* 14:21–36.
- Job DE, Whalley HC, McConnell S, Glabus M, Johnstone EC, Lawrie SM (2003): Voxel-based morphometry of grey matter densities in subjects at high risk of schizophrenia. *Schizophr Res* 64:1–13.

22. Chua SE, Cheung C, Cheung V, Tsang JT, Chen EY, Wong JC, *et al.* (2007): Cerebral grey, white matter and CSF in never-medicated, first-episode schizophrenia. *Schizophr Res* 89:12–21.
23. Wright IC, Rabe-Hesketh S, Woodruff PW, David AS, Murray RM, Bullmore ET (2000): Meta-analysis of regional brain volumes in schizophrenia. *Am J Psychiatry* 157:16–25.
24. Frodl T, Schaub A, Banac S, Charypar M, Jager M, Kummner P, *et al.* (2006): Reduced hippocampal volume correlates with executive dysfunctioning in major depression. *J Psychiatry Neurosci* 31:316–325.
25. Wu J, Buchsbaum MS, Gillin JC, Tang C, Cadwell S, Wiegand M, *et al.* (1999): Prediction of antidepressant effects of sleep deprivation by metabolic rates in the ventral anterior cingulate and medial prefrontal cortex. *Am J Psychiatry* 156:1149–1158.
26. Benedetti F, Bernasconi A, Pontiggia A (2006): Depression and neurological disorders. *Curr Opin Psychiatry* 19:14–18.
27. Sheline YI, Gado MH, Kraemer HC (2003): Untreated depression and hippocampal volume loss. *Am J Psychiatry* 160:1516–1518.
28. Benjamini Y, Hochberg Y (2000): Controlling the false discovery rate: A practical and powerful approach to multiple testing. *J Roy Stat Soc* 57:289–300.
29. Maldjian JA, Laurienti PJ, Kraft RA, Burdette JH (2003): An automated method for neuroanatomic and cytoarchitectonic atlas-based interrogation of fMRI data sets. *Neuroimage* 19:1233–1239.
30. Goldstein JM, Goodman JM, Seidman LJ, Kennedy DN, Makris N, Lee H, *et al.* (1999): Cortical abnormalities in schizophrenia identified by structural magnetic resonance imaging. *Arch Gen Psychiatry* 56:537–547.
31. Gur RE, Turetsky BI, Bilker WB, Gur RC (1999): Reduced gray matter volume in schizophrenia. *Arch Gen Psychiatry* 56:905–911.
32. Heckers S, Konradi C (2002): Hippocampal neurons in schizophrenia. *J Neural Transm* 109:891–905.
33. McDonald C, Bullmore ET, Sham PC, Chitnis X, Wickham H, Bramon E, *et al.* (2004): Association of genetic risks for schizophrenia and bipolar disorder with specific and generic brain structural endophenotypes. *Arch Gen Psychiatry* 61:974–984.
34. Smith ME (2005): Bilateral hippocampal volume reduction in adults with post-traumatic stress disorder: A meta-analysis of structural MRI studies. *Hippocampus* 15:798–807.
35. Kantarci K, Jack CR, Jr. (2003): Neuroimaging in Alzheimer disease: An evidence-based review. *Neuroimaging Clin N Am* 13:197–209.
36. Bremner JD, Narayan M, Anderson ER, Staib LH, Miller HL, Charney DS (2000): Hippocampal volume reduction in major depression. *Am J Psychiatry* 157:115–118.
37. Dhikav V, Anand KS (2007): Is hippocampal atrophy a future drug target? *Med Hypotheses* 68:1300–1306.
38. Maclean PD (1955): The limbic system (“visceral brain”) and emotional behavior. *AMA Arch Neurol Psychiatry* 73:130–134.
39. Hadland KA, Rushworth MF, Gaffan D, Passingham RE (2003): The effect of cingulate lesions on social behaviour and emotion. *Neuropsychologia* 41:919–931.
40. Voigt BA, Laureys S (2005): Posterior cingulate, precuneal and retrosplenial cortices: cytology and components of the neural network correlates of consciousness. *Prog Brain Res* 150:205–217.
41. Kennerley SW, Walton ME, Behrens TE, Buckley MJ, Rushworth MF (2006): Optimal decision making and the anterior cingulate cortex. *Nat Neurosci* 9:940–947.
42. Volz KG, Schubotz RI, von Cramon DY (2006): Decision-making and the frontal lobes. *Curr Opin Neurol* 19:401–406.
43. Volz KG, Schubotz RI, von Cramon DY (2005): Variants of uncertainty in decision-making and their neural correlates. *Brain Res Bull* 67:403–412.
44. Shenton ME, Dickey CC, Frumin M, McCarley RW (2001): A review of MRI findings in schizophrenia. *Schizophr Res* 49:1–52.
45. Lawrie SM, Abukmeil SS (1998): Brain abnormality in schizophrenia. A systematic and quantitative review of volumetric magnetic resonance imaging studies. *Br J Psychiatry* 172:110–120.
46. Quirk GJ, Garcia R, Gonzalez-Lima F (2006): Prefrontal mechanisms in extinction of conditioned fear. *Biol Psychiatry* 60:337–343.
47. Sotres-Bayon F, Bush DE, LeDoux JE (2004): Emotional perseveration: An update on prefrontal-amygdala interactions in fear extinction. *Learn Mem* 11:525–535.
48. Shackman AJ, Sarinopoulos I, Maxwell JS, Pizzagalli DA, Lavric A, Davidson RJ (2006): Anxiety selectively disrupts visuospatial working memory. *Emotion* 6:40–61.
49. Taymans JM, Van den Haute C, Baekelandt V (2006): Distribution of PINK1 and LRRK2 in rat and mouse brain. *J Neurochem* 98:951–961.